

# Understanding Your **Breast Cancer** Pathology Report\*



\*Note: Your pathology report may contain all or some of the sections covered in this guide. Remember, your healthcare team is always available to help you through this process and answer your questions.

HER  
navigator



# Your Clinical History

## Questions this section may answer

- How was your breast abnormality discovered?
- What were your doctor's impressions of the breast abnormality before your procedure?
- What type of procedure did you have?

My breast abnormality was discovered through:

- BREAST SELF-EXAM (BSE)
- CLINICAL BREAST EXAM (CBE)
- MAMMOGRAPHY
- OTHER \_\_\_\_\_

Additional information (if any) from my doctor:

---

---

The type of procedure my doctor performed to obtain a sample of my abnormal breast tissue was:

- FINE NEEDLE ASPIRATION (using a small needle to draw out a sample of breast mass)
- ULTRASOUND-GUIDED CORE NEEDLE BIOPSY (using an ultrasound image to locate a breast mass that is too small to be felt)
- STEREOTACTIC-GUIDED CORE NEEDLE BIOPSY (using a special mammography machine to locate a breast mass that is too small to be felt)
- OTHER \_\_\_\_\_

# Your Specimen

## Questions this section may answer

- Which breast was your tissue sample or biopsy taken from during your procedure?
- Which section of that breast?
- Were your axillary lymph nodes (under the arm) included as part of the sample?

1. My breast tissue sample or biopsy was taken from my:

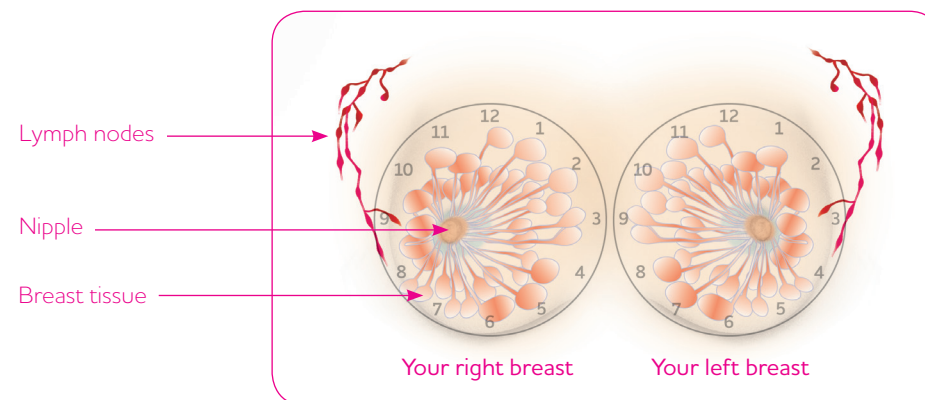
- LEFT BREAST
- RIGHT BREAST

2. The sample was taken from this section of the breast (see figure below and circle the area):

---

3. A sample of my lymph nodes (axillary) was also taken:

- YES
- NO



Your doctor may use a clock to refer to the area your sample was taken from, for example, "right breast, 11:00 position." This diagram can help you see what that means. You can also use this diagram to circle the area your sample was taken from.

# Your Tissue Sample— Gross Description

## Questions this section may answer

- What was the size of your tissue sample?
- What does this factor mean to your diagnosis?

This section will describe the **size** of your breast tissue sample. **Size** is the most important part of describing the sample because it helps to determine your cancer stage. The size may be measured in centimeters (cm) or by using a scale ranging from T0 to T4. This is part of a scale called TNM, which is explained further on page 8. The larger the tumor, the more it may have grown into the breast tissue.

Characteristics of my breast tissue sample:

Size: \_\_\_\_\_

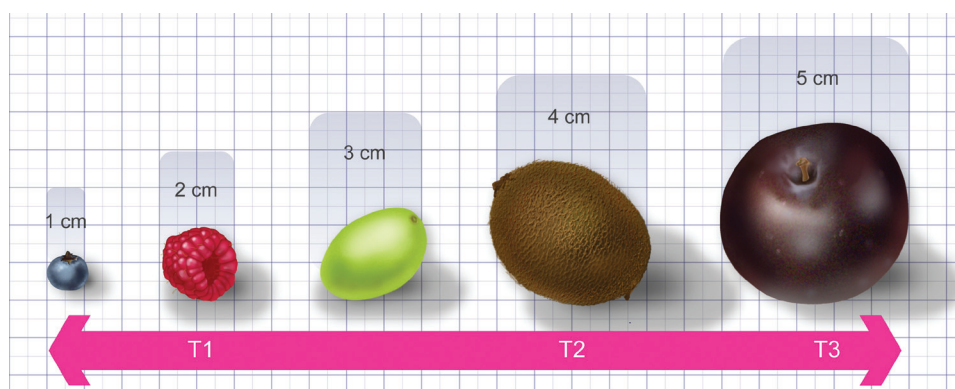


Diagram not shown to actual size.

# Your Tissue Sample— Microscopic Description

## Questions this section may answer

- What do your cancer cells look like under a microscope?
- Is your cancer noninvasive or invasive?
- How fast are the cells growing and what is the grade of your breast cancer?

This section details how your cancer cells looked under a microscope. It will tell you what kind of cancer you have, either:

- **Noninvasive** (in situ), which means that the cancer is confined to the ducts or lobules in the breast
- **Invasive**, which means that the cancer has started to spread to surrounding breast tissue

Your lymph node involvement also makes a difference. This section will also tell you how many lymph nodes in your sample had cancer in them. When more lymph nodes are involved, your cancer may be more threatening.

**Tumor grade** (also known as the Scarff-Bloom-Richardson grade) is used to determine the grade of invasive cancer. It is based on 3 factors:

- **Tubule formation** (how many cancer cells are in tubule formation—more is better)
- **Mitotic count** (how many cancer cells are in the process of dividing—fewer is better)
- **Nuclear grade** (how closely the cancer cells resemble normal cells)

Each of these factors is assigned a score between 1 and 3. These are then added together for a combined score between 3 and 9.

- A score of 3, 4, or 5 is assigned a grade of 1, which means that the cells are well differentiated and low grade (not growing rapidly)
- A score of 6 or 7 is assigned a grade of 2, which means that the cells are moderately differentiated and medium grade
- A score of 8 or 9 is assigned a grade of 3, which means that the cells are poorly differentiated and high grade (growing and spreading more aggressively)

My breast abnormality is:  NONINVASIVE  INVASIVE

My lymph nodes tested positive for cancer cells:  YES  NO

If yes, how many nodes: \_\_\_\_\_

The grade of my tumor is:  1  2  3

**In situ** – another way of saying that your breast cancer is noninvasive.

## Special Tests or Markers\*

### Questions this section may answer

- Is your breast cancer estrogen-receptor positive or progesterone-receptor positive?
- Is your breast cancer negative for hormone receptors?
- Is your breast cancer HER2+?
- If any of these factors are positive, what does it mean?

**Hormone receptors** on your breast cancer cells mean that the cells grow when hormones from your body attach to the receptors. If your breast cancer is estrogen-receptor positive or progesterone-receptor positive, you may benefit from hormonal therapy.

You will also learn the **HER2** status of your breast cancer from your pathology report. HER2+ cancer cells have more HER2 receptors than normal cells, causing them to grow and divide. HER2+ breast cancer is considered aggressive. The FDA-approved tests used to determine HER2 status are shown on the right.

\*This section is not all-inclusive, as there are many different tests and special markers for breast cancer.

## Special Tests or Markers (continued)

My hormone status is:

Estrogen receptors:  POSITIVE  NEGATIVE

Progesterone receptors:  POSITIVE  NEGATIVE

My HER2 status was tested by:  IHC  FISH  CISH

My HER2 results were:

IHC score:  0  1+  2+  3+

FISH results:  +  -

CISH results:  +  -

This means my tumor's HER2 status is:

POSITIVE

NEGATIVE

**IHC (immunohistochemistry)** – a test that gives a score of 0 to 3+ to indicate the number of HER2 receptor proteins on breast cancer cells. A tumor with a score of 2+ may need further evaluation to determine if it is positive, while a tumor with a score of 3+ is considered positive.

**FISH (fluorescence in situ hybridization)** – a test that determines if extra copies of HER2 receptors are present on breast cancer cells. Results are shown as positive or negative.

**CISH (chromogenic in situ hybridization)** – a test that determines if extra copies of HER2 receptors are present on breast cancer cells. Results are shown as positive or negative.

# Stage of Breast Cancer

## Questions this section may answer

- What stage is your breast cancer?
- How was this determined?
- What does your stage mean for your treatment?

Your pathologist and doctor have determined the stage of your breast cancer using some of the important factors from your pathology report.

Breast cancer stage is determined using the **TNM scale**, which includes size (T), lymph node involvement (N), and whether or not the cancer has spread beyond the breast (M).

My TNM score is:

---

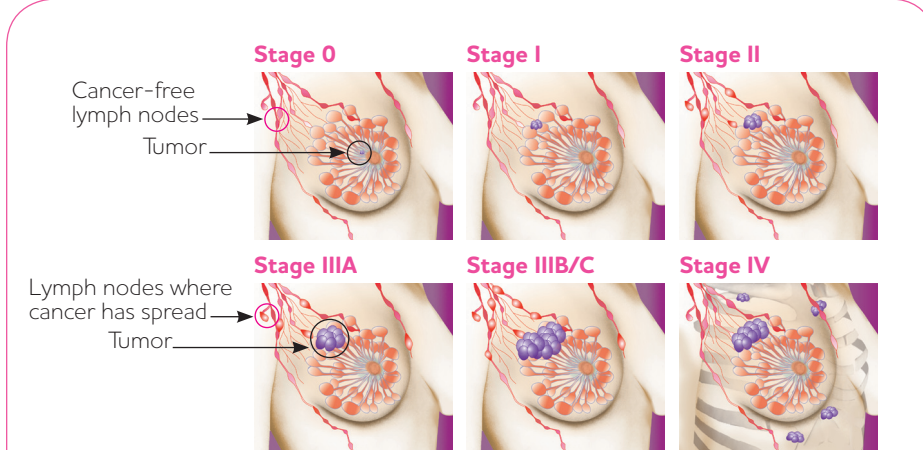
---

My breast cancer stage is:

---

---

---



The diagram shows six stages of breast cancer progression on a female torso. Stage 0 shows a tumor in the ducts with cancer-free lymph nodes. Stage I shows a larger tumor still within the ducts. Stage II shows a tumor that has spread to some lymph nodes. Stage IIIA shows a tumor that has spread to axillary lymph nodes. Stage IIIB/C shows a tumor that has spread to the chest wall and skin, and to lymph nodes near the breastbone. Stage IV shows a tumor that has metastasized to other body organs like the brain or bones.

**Stage 0** cancers are noninvasive and confined to the ducts or lobules.

**Stage I** cancers are invasive but do not involve lymph nodes. They are 2 cm or smaller.

**Stage II** cancers are invasive and are generally between 2 cm and 5 cm. They have either not spread into lymph nodes at all, or have only spread into some lymph nodes under the arm.

**Stage IIIA** cancers are invasive and have spread to axillary lymph nodes. **Stage IIIB/C** cancers have spread to the chest wall and/or skin of the breast, and to lymph nodes near the breastbone or collarbone.

**Stage IV** cancers have metastasized, which means they have spread to other body organs like the brain or bones.

## What's Next?

Your doctor now has the information needed to determine what type of breast cancer treatment is right for you.

*Your pathology report can be confusing and use terminology that is unfamiliar to you, so remember that your healthcare team is always here to help! They can assist you in addressing any questions brought about by your pathology report.*



